

Intracerebral Hemorrhage with Severe Ventricular Involvement --External Ventricle Drainage for Acute Obstructive Hydrocephalus

Xuejian Wang*, Yang Chen, Zhifeng Wang, Ming Qian

Department of Neurosurgery, The Second Hospital Affiliated to Nantong University, Nantong University, Nantong, PR China

Email address:

6841441@163.com (Xuejian Wang)

*Corresponding author

To cite this article:

Xuejian Wang, Yang Chen, Zhifeng Wang, Ming Qian. Intracerebral Hemorrhage with Severe Ventricular Involvement --External Ventricle Drainage for Acute Obstructive Hydrocephalus. *Clinical Neurology and Neuroscience*. Vol. 1, No. 3, 2017, pp. 56-59.

doi: 10.11648/j.cnn.20170103.12

Received: March 20, 2017; Accepted: April 12, 2017; Published: May 24, 2017

Abstract: *Background and Purpose:* The objective was to analyze the feasibility of an External Ventricle Drainage (EVD) for an obstructive hydrocephalus in patients with severe ventricular hemorrhage. *Methods:* In this retrospective study, from October 2012 to January 2014 in our department, 23 patients received an EVD for obstructive hydrocephalus. The duration of required EVD, risk factors, and therapeutic effect were analyzed. *Results:* Twenty three patients were enrolled; Hypertensive cerebral hemorrhage broken into ventricles and caused hydrocephalus in 19 cases, of which 14 cases led an EVD in single lateral ventricle forehead (five cases in left; nine in right side), 5 cases bilateral lateral ventricle forehead drainage; survival for 18 cases, but one case died of pulmonary infection; 4 cases need a further ventriculo-peritoneal shunt. Vascular malformations hemorrhage patients underwent single lateral EVD, bilateral drainage in one case; survived for three cases, one case died due to organ failure after infection; one case needs a further ventriculo-peritoneal shunt. *Conclusion:* Our data suggest that EVD is a safe and feasible way for treatment of acute obstructive hydrocephalus after intraventricular hemorrhage. After treatment by using an EVD for acute obstructive hydrocephalus, it can relieve patient's condition and gain time to further save lives.

Keywords: Intracerebral Hemorrhage, Obstructive Hydrocephalus, External Ventricle Drainage, Intraventricular Hemorrhage, Therapy

1. Introduction

Acute obstructive hydrocephalus is an emergency incident and need quickly manage to relieve intracranial pressure, to gain time for further treatment [1]. EVD can quickly relieve intracranial pressure, and also reach the aim to drainage of intraventricular hemorrhage in cases of cerebral hemorrhage. Urokinase and other drugs were inserted by EVD to dissolve a cerebral hemorrhage, to achieve the purpose of treatment and significantly reduce the proportion of late ventriculo-peritoneal shunt. From October 2010 to January 2014, 23 cases of acute obstructive hydrocephalus were treated in our department with hypertensive intracerebral hemorrhage broken into ventricles in 19 cases, vascular malformations in 4 cases. All these acute obstructive hydrocephalus cases were treated with an external ventricle drainage (EVD), and observed and follow-up treatment effect.

Summarized as follows:

2. Material and Methods

Ethics approval and consent to participate:

This research has been approved by the ethics committee of the Second Hospital affiliated to Nantong University. Informed consent has been obtained and this investigation has been conducted according to the principles expressed in the Declaration of Helsinki. And the authors have obtained written informed consent of all the tissues.

2.1. Patient Population

Twenty-three patients (9 female and 14 male; male/female ratio 1.6) with a mean age of 43.7 years (range from 29 to 72 years) were treated with an EVD for intraventricular blood. All patients exhibited acute hydrocephalus diagnosed by the

initial CT or MRI scan with or without blood clots obstructing the ventricles. Clinical manifestations: conscious in 12 cases, shallow-moderate coma in 8 cases, the deep coma in 3 cases. Hypertensive intracerebral hemorrhages were in 19 cases, cerebral vascular malformation hemorrhage in 4 cases.

2.2. Surgical Procedure

All cases are clear presence of acute obstructive hydrocephalus, with or without intraventricular hemorrhage. All cases were performance of the intracranial hypertension. The access side was chosen as the side of the lateral ventricle containing the largest amount of blood or the largest dilation, main in right forehead of lateral ventricle. In cases with bilateral massive inundation, the access was bilateral. In the presence of a ventricular vascular malformation or aneurysm, an approach from that side was avoided. Routine ipsilateral ventricle was punctured for the single ventricle hematocoele in 19 cases, double lateral ventricles drainage in 4 cases for bilateral ventricles hemorrhage.

The surgery method are as follows: After routine disinfection, supine, head elevation to 20-30°, the access was 1 cm precoronal, 2-3 cm from lateral to the midline, through a 1 cm bur hole. Dural was incision in “+” shaped, coagulated hemostasis. Puncture with core needle puncture needle was in the direction toward imaginary ligature midpoint of the bilateral external auditory canal and avoided cortical blood vessels. The depth of needle was inserted in 4-6mm, after a sense of breakthroughs, to get into the lateral ventricle forehead. Cerebrospinal fluid outflow is visible when pull out the needle core, and then inserted a more 0.5-1cm in it. Next, EVD tubes was fixed, and sutured. Height of EVD was according to the patient's intracranial pressure and the amount and speed of drainage.

To cases of excessive intraventricular hemorrhage or even cast ventricle, we inject urokinase into intraventricular to promote dissolve blood clots, which could speed up the recovery of cerebrospinal fluid circulation. The method of urokinase application: 50,000 U of urokinase was dissolved in 5 ml 0.9% sodium chloride solution and injected into intraventricular according EVD. Drainage was opened after closed for 2 hours. Urokinase solution could be used again 1 d after. In the process of drainage, the amount of drainage and color was observed and recorded. If necessary, urokinase was several injected for treatment. Up, we injected a total four times of urokinase. The five cases in the late were added a lumbar puncture catheter assisted drainage and treatment of intraventricular hemorrhage.

The longest indwelling time of EVD was a week, 3-5 days in normal. In the course of treatment, once the clots disappeared and obstruction was eliminated in the timely review of head CT, EVD was timely Clipping. If intracranial pressure was not increased in more than 1 d (> 24h), and disturbance of consciousness does not aggravate in these cases, EVD was removed.

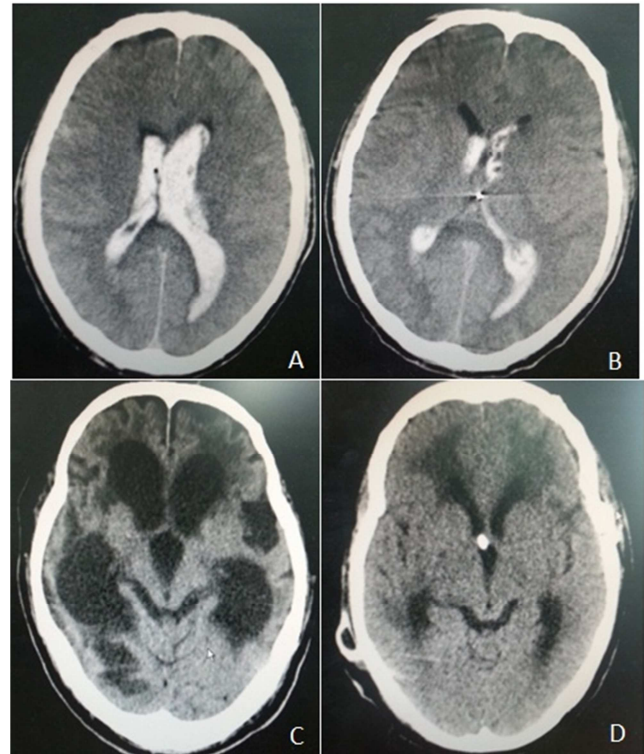


Figure 1. A patient was ventricle haemorrhage with associated hydrocephalus and blood in the third and both lateral ventricles. (A) Pre operative CT scan showing ventricle haemorrhage with associated hydrocephalus and blood in the third and both lateral ventricles; (B) an EVD was led in single lateral ventricle, and ventricle haemorrhage was smaller in CT scan two days later; (C) three month later, this patient shows headache, a declining level of consciousness and function. The clinical picture in CT is ventriculomegaly and periventricular edema; (D) After ventriculo-peritoneal shunt (VPS), it's brain CT scan showed that ventriculomegaly become to normal more or less and periventricular edema is alleviated.

3. Results

The group consisted of 23 cases of acute obstructive hydrocephalus with or without intraventricular hemorrhage: hypertensive intracerebral hemorrhage breaking into the ventricle were in 19 cases, of which 14 routine ipsilateral lateral ventricle forehead EVD (5 cases in the left side and 9 cases in right), 5 cases underwent bilateral lateral forehead EVD, including two cases with the use of a lumbar puncture; 18 cases were survival postoperative, 1 case died of pulmonary infection, and 4 cases need a further ventriculoperitoneal shunt in follow-up; 4 cerebral hemorrhage patients because of vascular malformations underwent single ventricle drainage in three (one case in left and two in right side) and bilateral EVD in one case, of which 3 cases was survival, one case died due to organ failure after infection, 1 case required a secondary ventricle-peritoneal shunt. Postoperative follow-up head CT, it suggested intracranial acute hydrocephalus was improved.

4. Discussions

Acute obstructive hydrocephalus due to intraventricular hemorrhage or ischemia was neurosurgery emergency. Acute

cerebrospinal fluid circulation disorder was caused by cerebral hemorrhage, cerebral edema after cerebral ischemia, and some other reasons. Hydrocephalus was increasing to expansion of the ventricular system, and increased ventricular tension. All cases had performance of intracranial hypertension, aggravated disturbance of consciousness, coma or even death in severe cases. EVD is feasible to relieve the intraventricular pressure, drainage of cerebrospinal fluid, and to gain time for further treatment [1, 5, 7].

Reason for the occurrence of acute hydrocephalus caused by stroke, we summarized down the following two reasons: (a) variety reasons of cerebral hemorrhage, such as: hypertensive intracerebral hemorrhage, spontaneous subarachnoid hemorrhage, and so on, resulted in the drainage disorder or malabsorption of cerebrospinal fluid in the ventricular system. Cerebrospinal fluid was accumulated in the ventricular system which could impact cerebrospinal fluid circulation. For example, aqueduct was obstructed by bleeding, and third ventricle was block by hemorrhage [3, 4, 11]; (b) hypertension stroke, cerebral infarction and other reasons cause brain swelling, shift of brain midline, ventricular compression, which obstructed the pathway of cerebrospinal fluid circulation, and resulted in acute hydrocephalus [2, 8]. After the formation of acute obstructive hydrocephalus, intracranial pressure was increased because disorder of cerebrospinal fluid circulation, which seriously affected the survival of the state and the consciousness of the patients, or even death in severe cases. Clinical condition should be closely observed, and the brain CT examination should be considered in a timely manner when necessary. Once diagnosed, handle should be actively.

23 cases of acute obstructive hydrocephalus admitted to our department from October 2010 to January 2014, treated with EVD. Of this series, hypertensive cerebral hemorrhage broken into ventricles in 19 cases, and cerebral hemorrhage because of vascular malformations in 4 cases. Bilateral lateral drainage in six cases, 6 cases in left ventricle drainage, 11 cases in the right side. Principles of catheter drainage in our department: The access side was chosen main in right forehead of lateral ventricle or bilateral. The method of urokinase application: 50,000 U of urokinase was dissolved in 5 ml 0.9% sodium chloride solution and injected into intraventricular according EVD. Drainage was closed for 2 hours before opened. In the process of drainage, the amount of drainage and color was observed and recorded. Depending on the blood volume and effect of drainage, urokinase can be used continuously for several days. After injection of urokinase, changes should be closely observed, in condition such as: increased disturbance of consciousness, restlessness, and high blood pressure. Once met, EVD should be opened in a timely manner. If fresh bleeding or the patient's condition does not get better after opened, a timely head CT is in consideration. As early as 1995, Rohde et al [10] reported EVD in the intraventricular hemorrhage achieved satisfactory results combined with the use of rt-PA treatment. In 2000, Naff et al [9] reported that a group of 12 patients with intraventricular hemorrhage was treated by EVD combined with urokinase injection therapy,

and achieved satisfactory results. EVD was clipping for 24 hours inner 3-5 days once acute hydrocephalus was relieved. If disturbance of consciousness is not increased, EVD was removal, which can't be indwelling for more than a week. Huttner et al [6] EVD was clamping for one day in cases whose intraventricular pressure is no more than 20 mmHg up to 24 hours, than EVD was removed if none expansion of the ventricular system in review of head CT. For hydrocephalus cases in the latter follow-up, a further ventricular-peritoneal shunt was alternative. 7 cases in this series required a further ventricular-peritoneal shunt.

To cases of obstructive intraventricular hemorrhage, we treated with use of a lumbar puncture external drainage (LED) in the latter part of these cases. In the early, ventricular system is still in a state of obstruction, not yet recanalization, EVD with a LED can promote the discharge of cerebral hemorrhage. Once clear there is no obstruction in the ventricular system, especially after the removal of EVD, we continue with the use of LED. We consider that although EVD alone is effective to drainage small lateral ventricle hemorrhage. To cast ventricle or larger blood clots, EVD only is limited, especially for the third and fourth ventricle hemorrhage cases which was less exposure, less direct effective, and dissolved ineffective. If oppression to hypothalamus, brain stem and other intracranial important anatomical structures can't be quickly released, this would affect the efficacy. EVD plus ELD can help accelerate the dissolution and removal of intracranial hemorrhage, relieve intracranial pressure. Huttner et al [6] similar to our point of view, that EVD plus ELD were effective to obstructive hydrocephalus of intraventricular hemorrhage than EVD only, and found by statistics that EVD combined with ELD can significantly shortened removal time than separate EVD.

In this series, 2 cases met an infection of non-ventricular system, and ultimately death, but no one of infections in ventricular system. So we believe that attention to aseptic technique intraoperative and extubation time of EVD can effectively avoid the incidence of intracranial infection. Sykora et al [12] found that irritating injuries in patients can regulate the body's ability to strengthen fight infection; at the same time, infection in stroke cases were main in indwelling time of catheter and lung infections, rather than intracranial infection.

5. Conclusion

Acute obstructive hydrocephalus need be timely detected, and can be treated by the use of EVD which can effectively alleviate the condition, and gain time for further treatment. To the cases of intraventricular hemorrhage, EVD combined with urokinase to dissolve hemorrhage clot can get a very good therapeutic effect. Aseptic technique intraoperative and EVD timely removed postoperative can effectively prevent intracranial infection.

Abbreviation List

External Ventricle Drainage (EVD)
Lumbar puncture external drainage (LED, ELD)
Computed Tomography (CT)

Ethics Approval and Consent to Participate

This research has been approved by the ethics committee of the Second Hospital affiliated to Nantong University (2016002). Informed consent has been obtained and this investigation has been conducted according to the principles expressed in the Declaration of Helsinki. And the authors have obtained written informed consent of all the tissues.

Acknowledgements

This research supported by: (1) Young Medical Project of Nantong City Health Bureau (WQ2014016); (2) Traditional Chinese medicine science and technology project in Jiangsu province (No. YB2015113); (3) the science and technology program of Nantong city (no.: MS12015016).

References

- [1] Adams RE, Diringer MN: Response to external ventricular drainage in spontaneous intracerebral hemorrhage with hydrocephalus. *Neurology* 50: 519–523, 1998.
- [2] Brott T, Broderick J, Kothari R, Barsan W, Tomsick T, Sauerbeck L, Spilker J, Duldner J, Khoury J: Early hemorrhage growth in patients with intracerebral hemorrhage. *Stroke* 28: 1-5, 1997.
- [3] Cherian S, Whitelaw A, Thoresen M, Love S: The pathogenesis of neonatal post-hemorrhagic hydrocephalus. *Brain Pathol* 14: 305-311, 2004.
- [4] Cramer BC, Walsh EA. Cisterna magna clot and subsequent post-hemorrhagic hydrocephalus. *Pediatr Radiol* 31: 153-159, 2001.
- [5] Engelhard HH, Andrews CO, Slavin KV, Charbel FT: Current management of intraventricular hemorrhage. *Surg Neurol* 60: 15–21, 2003.
- [6] Huttner HB, Nagel S, Tognoni E, Köhrmann M, Jüttler E, Orakcioglu B, Schellinger PD, Schwab S, Bardutzky J: Intracerebral hemorrhage with severe ventricular involvement: lumbar drainage for communicating hydrocephalus. *Stroke* 38: 183-187, 2007.
- [7] Liliang PC, Liang CL, Lu CH, Chang HW, Cheng CH, Lee TC, Chen HJ: Hypertensive caudate hemorrhage prognostic predictor, outcome, and role of external ventricular drainage. *Stroke* 32: 1195-1200, 2001.
- [8] Mayer SA. Ultra-early hemostatic therapy for intracerebral hemorrhage. *Stroke* 34: 224-229, 2003.
- [9] Naff NJ, Carhuapoma JR, Williams MA, Bhardwaj A, Ulatowski JA, Bederson J, Bullock R, Schmutzhard E, Pfausler B, Keyl PM, Tuhim S, Hanley DF: Treatment of intraventricular hemorrhage with urokinase: effects on 30-Day survival. *Stroke* 31: 841-847, 2000.
- [10] Rohde V, Schaller C, Hassler WE: Intraventricular recombinant tissue plasminogen activator for lysis of intraventricular haemorrhage. *J Neurol Neurosurg Psychiatry* 58: 447-451, 1995.
- [11] Shooman D, Portess H, Sparrow O: A review of the current treatment methods for posthaemorrhagic hydrocephalus of infants. *Cerebrospinal Fluid Res* 30; 6: 1, 2009.
- [12] Sykora M, Diedler J, Poli S, Rizos T, Turcani P, Veltkamp R, Steiner T: Autonomic shift and increased susceptibility to infections after acute intracerebral hemorrhage. *Stroke* 42: 1218-1223, 2011.