

Extrapyramidal Involvement as a Manifestation of ROBO3 Mutation in HGPPS: A Case Report and Review of Literatures

Matineh Heidari¹, Tara Khoeini¹, Mostafa Almasi Dooghaee¹, Omid Aryani², Zahra Mirzaasgari^{1,*}

¹Neurology Department of Firoozgar Hospital, Iran University of Medical Sciences, Tehran, Iran

²Department of Neuroscience, Iran University of Medical Science, Tehran, Iran

Email address:

Mirzaasgari@gmail.com (Z. Mirzaasgari)

*Corresponding author

To cite this article:

Matineh Heidari, Tara Khoeini, Mostafa Almasi Dooghaee, Omid Aryani, Zahra Mirzaasgari. Extrapyramidal Involvement as a Manifestation of ROBO3 Mutation in HGPPS: A Case Report and Review of Literatures. *Clinical Neurology and Neuroscience*.

Vol. 6, No. 1, 2022, pp. 1-5. doi: 10.11648/j.cnn.20220601.11

Received: October 1, 2021; **Accepted:** October 28, 2021; **Published:** January 12, 2022

Abstract: HGPPS (horizontal gaze palsy with progressive scoliosis) presents in early childhood ages and one of the cardinal manifestations of the syndrome, progressive scoliosis, is the main disabling feature which usually seeks for orthopedic correction surgeries in early years. Nevertheless, the presence of scoliosis has not been explained yet by the pathogenesis of the disease, the ROBO3 mutation, which is a well-known pathology for gaze palsy by failure of axonal decussation toward the pontomedullary junction. This article highlights a novel case of HGPPS with prominent extrapyramidal findings including torticollis, cervical dystonia and facial spasm along with classic clinical, imaging and genetic correlation. Aiming to investigate the prevalence of extrapyramidal signs in this syndrome, the published cases of HGPPS in the literature have been reviewed in this study. 32% of all HGPPS cases between years of 1975 to 2020 founded to have one or more extrapyramidal features and the dystonia was the most reported sign which even proceed to the presence of scoliosis. Regarding to the fact that the scoliosis could be as a consequence of axial dystonia, its relationship to ROBO3 mutation can be explained by structural and functional changes toward the brainstem and cerebellum, which are involved in this syndrome and known to contribute with the extrapyramidal system. Knowing this possibility, not only could solve the 35-year mystery of scoliosis in the syndrome, but also would be considered as a target of treatment to prevent scoliosis in the future.

Keywords: Horizontal Gaze Palsy with Progressive Scoliosis, Extrapyramidal, Dystonia, Movement Disorder, Neurogenetic

1. Introduction

Horizontal gaze palsy with progressive scoliosis (HGPPS), is an autosomal recessive disease due to ROBO3 mutation, which results in dysregulation of axonal midline decussation process of motor and sensory pathways during the development of the central nervous system [1]. Uncrossed corticospinal, dorsal column and medial lemniscus pathways leads to malformation and malfunction of the inferior pons and medulla which is visualized with a specific imaging appearance [2] There are many case reports since 1975 to the recent, focusing on the clinical features, structural and functional MRI correlations and detailed genetic mapping of the disease [3, 4], Nevertheless, some ambiguities about the

pathophysiology of the syndrome still exist. The scoliosis, one of the cardinal manifestations of the syndrome is not fully understood yet by the ROBO3 malfunction. Furthermore, persistence of some unusual clinical findings reported in various published cases such as torticollis, facial spasm and cervical dystonia, have not been favorably explained or linked to the disease. Recently it has been addressed that torticollis which has been reported in several studies, can be a reason for discovery [5].

In this article, following the presentation of a confirmed case of HGPPS with remarkable extrapyramidal signs along with classical manifestations of the syndrome, the previous published cases of HGPPS are evaluated with respect to extrapyramidal involvement, in order to estimate the

prevalence of these signs in the course of the disease and to investigate the possible related underlying etiology to scoliosis and ROBO3 mutation.

2. Case Presentation

A 28-year-old Afghan male referred to Firoozgar hospital neurology clinic for pre-operation consultant of scoliosis correction surgery. The patient mentioned he had a non-painful progressive spinal deviation more noticeable from his late childhood. He also complained of a neck deviation and eye blinking starting in the early childhood ages without any related etiology. His past history was unremarkable. He had no peri gestational event and had a normal development. His parents were related from second degree. Other members of his family including his parents, brothers and one sister were not affected. In his examination, despite a 45-degree scoliosis, he had complete horizontal gaze palsy with normal vertical eye movements and without any nystagmus; gaze palsy was not symptomatic for the patient. An intermittent facial spasm more prominent in the left side and head titubation with laterocollis to the Right, compatible with dystonic tremor also detected. other neurologic examinations were unremarkable. The electromyographic study was normal. In his brain MRI, pontine hypoplasia with deep midline clefts in the pons and medulla detected simulating a classical “tent shaped” fourth ventricle and “butterfly medulla” (figure 1). Patient referred for genetic testing of ROBO3 mutations. A novel homozygous variation as c. C677G p. T226R in the ROBO3 gene was detected and also was segregated in his parents. Both the parent was heterozygous for the variation too.

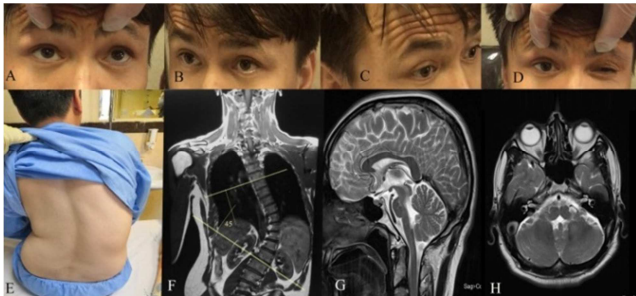


Figure 1. Physical examination findings and imaging of patient with HGPPS. A: normal vertical gaze. B and C: impaired horizontal gaze; patient corrects his gaze palsy with turning his head to the object. D: facial spasm and torticollis. E and F: scoliosis (45 degree). G and H classical MRI signs of tented 4th ventricle (G image) and butterfly pones (H image).

3. Discussion

From the first published case of HGPPS in 1975 to the recent, extrapyramidal signs have been occasionally reported along with cardinal manifestations of the disease, as facial myokymia was one of the significant signs of the very first reported patient with HGPPS [6] and some other extrapyramidal findings such as torticollis and head titubation, mentioned in many of afterward case reports;

Nevertheless, not only the pathophysiology of these signs has not been fully explained, but also in some level ignored to be considered as a part of the syndrome. Although some authors have been focusing on extrapyramidal findings in HGPPS by arranging them into different categories [5, 7], but there is no further investigation to any of those.

The young patient, was born from consanguineous parents both were heterozygous for the ROBO3 mutation, presented with cardinal manifestations of the disease; progressive scoliosis and horizontal gaze palsy. His clinical syndrome and characteristic MRI findings lead us to diagnosis of HGPPS which confirmed with genetic testing. What was significant about the patient was the presence of prominent extrapyramidal signs; including an intermittent facial spasm more in the left side, torticollis and dystonic head tremor which all had begun in early childhood ages, coexisting with the scoliosis as long as he could remember. The patient did not mention any history of head trauma or Bell's palsy which could be the reason for his facial spasm and also no structural pathologic lesion detected in his MRI to be congruent with this condition except the characteristic “butterfly” radiologic configuration of HGPPS due to hypoplastic pons and medulla. The torticollis was not due to muscle abnormalities because it intermittently appeared and disappeared. The frequency of head tremor was variable in specific postures and in active contraction, compatible with dystonic head tremor. The presence of those extrapyramidal findings was unexplained according to the literature and needed further explanation. In order to investigate the reasonable prevalence of extrapyramidal signs in HGPPS, all the published cases of HGPPS between year 1975 to 2020 extracted through the search engines of google scholar and PubMed with the key words for “HGPPS” and “Horizontal gaze palsy with progressive scoliosis”. The cases with combination of cardinal manifestations of the syndrome (scoliosis and horizontal gaze palsy) or one of them confirmed with MRI findings or genetic testing selected and then evaluated by the report of any extrapyramidal signs; including: torticollis, laterocollis, head titubation, head shaking abnormal, head posture, abnormal movement, head nodding, dystonia, parkinsonism, blepharospasm, facial myokymia, asynchronous blinks and Meigs syndrome.

A total number of 96 eligible cases of HGPPS detected. The age of definite diagnosis was from 7-month-old to 58-year-old. 30 cases had a sign of extrapyramidal involvement, consisting 32% of total reports. Torticollis was the most reported clinical finding correlate with extrapyramidal manifestation, observed in 43% of these cases [5, 8-11], followed by dystonic head tremor detected in 40% of cases [7, 12-15] and facial contraction developed in 20% of cases [7, 15, 16]. One patient showed the combination of facial spasm along with dystonic head tremor [6]. The mean age of developing extrapyramidal signs was 8.5-year-old and male to female ratio was 2:1. Some authors had a more detailed focus on extrapyramidal signs such as the presenting age of extrapyramidal signs and indicated that torticollis and head titubation (cervical dystonia) may even appear before the

cardinal manifestations of HGPPS [2, 8, 9, 14]. The detailed information of articles with extrapyramidal signs has shown in the tables 1 and 2.

Table 1. Detailed information of articles describing extrapyramidal signs in HGPPS between years of 1975 to 2020.

	Article information	Extrapyramidal signs	Number of patients
1	Clinical and Genetic Heterogeneity in Six Tunisian Families with Horizontal Gaze Palsy With Progressive Scoliosis: A Retrospective Study of 13 Cases. Sami Bouchoucha, 2020 [5]	torticollis	5
2	Neurologic features of horizontal gaze palsy and progressive scoliosis with mutations in ROBO3 T. M. Bosley. 2005 [7]	head shaking asynchronous blinks	53
3	Horizontal gaze palsy with progressive scoliosis can result from compound heterozygous mutations in ROBO3 W-M Chan-2006 [8]	torticollis	2
4	Horizontal gaze palsy and progressive scoliosis with two novel ROBO3 gene mutations in two Jordanian families Liqa A. Rousan 2019 [9]	torticollis	4
5	Horizontal gaze palsy and progressive scoliosis in a patient with congenital esotropia and inability to abduct. A case report. A Fernández-Vega Cueto. 2016 [10]	torticollis	1
6	Novel Homozygous Nonsense Mutation in the ROBO3 gene causing Torticollis and Horizontal Gaze Palsy with Progressive Scoliosis: A Tale of Two Brothers (P5. 143) W. Baek. 2016 [11]	torticollis	1
7	Horizontal gaze palsy with progressive scoliosis in a Moroccan family H. Handor. 2014 [12]	head tremor	3
8	Acquired Convergence Substitution in Horizontal Gaze Palsy and Progressive Scoliosis Associated with ROBO3 Mutations Berker Bakkak. 2012 [13]	head tremor	1
9	Horizontal gaze palsy with progressive scoliosis (HGPPS): The role of brain MRI and diffusion tensor imaging in diagnosis G. Haliloglu 2015 [14]	head titubation	2
10	Bilateral synergistic convergence associated with homozygous ROBO3 mutation (p. Pro771Leu) Arif O Khan. 2008 [15]	asynchronous blinking and head nodding	1
11	Familial paralysis of horizontal gaze Associated with pendular nystagmus, progressive scoliosis, and facial contract ion with myokymia JAMES A. 1975 [6]	facial myokymia	1
12	Horizontal gaze palsy and progressive scoliosis—a tale of two siblings with ROBO3 mutation Poornima Narayanan Nambiar. 2020 [16]	asynchrony blink	1

Table 2. Continued. Age, sex and specific details of HGPPS patients presenting extrapyramidal signs between years of 1975 to 2020.

	Age at presentation of extrapyramidal signs	Sex	Specific details
1	8-month, 8 month, 1-year-old, 7-year old, one was not indicated	4 males 1 female	Torticollis, which has been reported in several patients with HGPPS, can also be a reason for discovery torticollis was the presenting symptom in 4 of patients [5]
2	6, 9, 13, 17 and 20-year-old 5, 14 and 23-year-old	3 males 2 females 2males 1 female	Images captured from videotape revealing asynchronous blink in Patients E-2, D-1, and D2. In every case the final position of both lids was completely closed. [7]
3	4 months 5-year-old	male female	In both patients, torticollis and plagiocephaly were detected prior to the diagnosis of scoliosis [8]
4	7-year-old, 7-year-old, 16-year-old and 17-year-old	3 males 1 female	the scoliosis was progressive presenting as early as 1-year-old with torticollis The youngest patient in our cases (patient III-2), presented with torticollis before the development of scoliosis [9]
5	4-year-old	male	[10]
6	22-year-old	male	[11]
7	Not indicated	2 males one female	head tremor during gaze fixation attempts [12]
8	12-year-old	female	[13]
9	1-year-old 2-year-old	female	A 12-year-old girl was referred with abnormal head movements and thoracolumbar scoliosis. Her parents recognized abnormal eye movements and head titubation and progressive scoliosis, at the age of 1 y, and 7 y respectively [14]
10	9-year-old	female	At times she obliquely nodded her head with low amplitude and a high frequency, but this also was not consistent. She often blinked asynchronously, that is, at times the left eye blinked without the right eye and at other times the right eye blinked without the left eye [15]
11	30-year-old	male	Facial myokymia and associated continuous facial contraction were progressive for three years The intensity of facial contraction was variable on the right side but persistent on the left [16]
12	8-year-old	male	[16]

Despite quite noticeable reports of dystonia in HGPPS, minimal literature to date have been focusing on the possible pathophysiology related to ROBO3 mutation. In the other hand, the presence of scoliosis in the syndrome still remained miscellaneous in contrast to the well explained horizontal gaze

pals by uncrossed medial longitudinal fasciculus in the brainstem [3, 17]. While there are evidences suggesting that a subclinical paraspinal muscle dystonia could result in scoliosis [18], the two could relate in HGPPS as well. As it discussed earlier, not only dystonia could be seen in the course of

HGPPS, it could also be more noticeable prior to the diagnosis of scoliosis. The regional dystonia shown in cases of HGPPS in the cervical area (head titubation and torticollis), may reflect the presence of a more widespread subclinical dystonia to axial paraspinal muscles, which in consequence, scoliosis develops. Also, one study reported that the degree of scoliosis in HGPPS patients who visited with torticollis as an early manifestation was lower in comparison with those who brought to the clinic for scoliosis evaluation [5]. But how the dystonia and other extrapyramidal involvements can be explained by ROBO3 mutation?

Evidences have shown that the pathophysiology of dystonia may involve the malfunction of cholinergic brainstem cells and special parts of the cerebellum [19]. In confirmation to that, reduced cholinergic immunostaining in medulla, pons and cerebellar regions were identified in cases of isolated cervical dystonia [20]. In HGPPS, more extended to size reduction of the anterior-posterior diameter of pons and medulla, several DTI studies have shown similar size changes within the superior and middle cerebellar peduncles as well [21]. Also, the butterfly shape appearance of the medulla has been linked to the reduced size of inferior cerebellar peduncles [22], so the structural and functional changes in pons, medulla and cerebellum caused by ROBO3 mutation are expected to contribute to extrapyramidal dysfunction specifically dystonia in HGPPS.

Recently another hypothesis for the mechanism of scoliosis in HGPPS has been proposed by Chi-Wei Lin and colleagues in 2018; they suggested that a cortical dysregulation and impaired sensory input from the cortex as a result of the pontocerebellar tract agenesis happens in HGPPS [22] although this study did not mentioned dystonia, but the cortical dysregulation could support the theory of this investigation, in respect to the fact that dystonia is the consequence of imbalanced sensorimotor integration leading to abnormal postural tone as well [18]. This must be indicated that there is another theory suggesting cervical dystonia could be secondary to scoliosis and expected as a compensatory involuntary posture of the neck [23] but in a cross-control study it was questioned and an independent link between these two and a genetic predominancy were shown [24]. Furthermore, as it mentioned, some cases of HGPPS showed torticollis and cervical dystonia in infancy and early childhood ages before the appearance of scoliosis, which will reinforce the independency of developing dystonia.

4. Conclusion

Extrapyramidal involvement in HGPPS is not uncommon and cervical dystonia is the most reported sign through the literature, which may highlight the presence of an axial dystonia. Maldeveloped extrapyramidal tracts within pons, medulla and cerebellar peduncles and an impaired cortical sensory input/output from pontocerebellar tract agenesis resulting from ROBO3 mutation, can be a possible reason for axial dystonia contributing to progressive scoliosis in HGPPS.

The benefit of knowing extrapyramidal signs as a part of HGPPS syndrome, can be a target of treatment in order to reduce the progression of the scoliosis, the main disabling feature of the disease.

Competing Interests

The authors declare that they have no competing interests.

Contributors

M Heidari and Tara Khoeini prepared the first draft. M Almasi, Z Mirzaasgari and O Aryani, reviewed the manuscript for intellectual content. O Aryani performed genetic testing. T Khoeini and M Almasi prepared the figures. M Heidari prepared the final manuscript.

Ethical Approval Information

Not applicable. Consent for publication signed by the patient and attached in the supplementary data.

Data Sharing Statement

All data generated or analyzed during this study are included in this published article and its supplementary information files.

Acknowledgements

We thank professor Gholamali Shahidi (movement disorder specialist at IUMS) for his guidance to symptomatology of the patient. We also would like to thank Professor Mohammad Rohani (movement disorder specialist at IUMS) whose previous published case of HGPPS, leads us to proper diagnosis.

References

- [1] Jen J CC, Bosley TM, et al. Familial horizontal gaze palsy with progressive scoliosis maps to chromosome 11q23–25. *Neurology*. 2002 Aug 13; 59 (3): 432-5; doi: 10.1212/wnl.59.3.432.
- [2] Abu-Amro KK, Kapoor, S., Hellani, A., Monga, S., & Bosley, T. M. Horizontal gaze palsy and progressive scoliosis due to a deleterious mutation in ROBO3. *Ophthalmic Genet*. 2011 Nov; 32 (4): 212-6; doi: 10.3109/13816810.2011.574186.
- [3] Haller S, Wetzel SG, Lütsch J. Functional MRI, DTI and neurophysiology in horizontal gaze palsy with progressive scoliosis. *Neuroradiology*. 2008; 50 (5): 453-9; doi: 10.1007/s00234-007-0359-1.
- [4] Poncet A, Merlini L. DTI measurements of non-decussating fibers in defective axon guidance disorders (Horizontal gaze palsy and progressive scoliosis and Joubert syndrome). *Journal of Pediatric Neuroradiology*. 2015; 02 (02): 131-9; DOI: 10.3233/PNR-13054.

- [5] Sami Bouchoucha. Clinical and Genetic Heterogeneity in Six Tunisian Families with Horizontal Gaze Palsy with Progressive Scoliosis: A Retrospective Study of 13 Cases. *Frontiers in Pediatrics*. April 2020; <https://doi.org/10.3389/fped.2020.00172>.
- [6] JAMES A. SHARPE, M. D., J. L. SILVERSIDES, M. D., and R. D. G. BLAIR, M. D. Familial paralysis of horizontal gaze Associated with pendular nystagmus, progressive scoliosis, and facial contract ion with myokymia. *Neurology*. 1975; 25 (11): 1035-40. doi: 10.1212/wnl.25.11.1035.
- [7] T. M. Bosley. Neurologic features of horizontal gaze palsy and progressive scoliosis with mutations in ROBO3. *Neurology*. 2005 12; 64 (7): 1196-203; doi: 10.1212/01.WNL.0000156349.01765.2B.
- [8] W-M Chan, E I Traboulsi, B Arthur, N Friedman, C Andrews, and E C Engle. Horizontal gaze palsy with progressive scoliosis can result from compound heterozygous mutations in ROBO3. *J Med Genet*. 2006 Mar; 43 (3); doi: 10.1136/jmg.2005.035436.
- [9] Liqa A, Abu Baker L Qased, Ziad A Audat, et al. Horizontal gaze palsy and progressive scoliosis with two novel ROBO3 gene mutations in two Jordanian families. *Ophthalmic Genet*. 2019; 40 (2): 150-156; doi: 10.1080/13816810.2019.1592199.
- [10] A Fernández-Vega Cueto, J J Rodríguez-Ezcurra, I Rodríguez-Maiztegui. Horizontal gaze palsy and progressive scoliosis in a patient with congenital esotropia and inability to abduct. A case report. *Arch Soc Esp Oftalmol*. 2016 Dec; 91 (12): 592-595; doi: 10.1016/j.oftal.2016.05.002. Epub 2016 Jun 16.
- [11] W. Baek, J. Jen, H. Mamsa. Novel Homozygous Nonsense Mutation in the ROBO3 gene causing Torticollis and Horizontal Gaze Palsy with Progressive Scoliosis: A Tale of Two Brothers. *Neurology*. 2016; 86.
- [12] H. Handor, M. Laghmari, Z. Hafidi, R. Daoudi. Horizontal gaze palsy with progressive scoliosis in a Moroccan family. *Orthop Traumatol Surg Res*. 2014; 100 (2): 255-7; doi: 10.1016/j.otsr.2013.08.012.
- [13] Berker Bakbak and Tulay Kansu. Acquired Convergence Substitution in Horizontal Gaze Palsy and Progressive Scoliosis Associated with ROBO3 Mutations. *Informa healthcare*. 2012; doi.org/10.3109/01658107.2012.710920.
- [14] G. Haliloglu, C. Gunbey, E. Serdaroglu, K. Karlı Oguz. Hacettepe. Horizontal gaze palsy with progressive scoliosis (HGPPS): The role of brain MRI and diffusion tensor imaging in diagnosis. *European Journal of Paediatric Neurology*. 2015 19 (1): S48; doi: 10.1016/S1090-3798(15)30156-2.
- [15] Arif O. Khan, MD, Darren T. Oystreck, OC (C), Nada Al-Tassan, PhD, Latifa Al-Sharif, Bsc, Thomas M. Bosley, MD. Bilateral synergistic convergence associated with homozygous ROBO3 mutation. *American Academy of Ophthalmology*. 2008; DOI: <https://doi.org/10.1016/j.opthta.2008.08.010>.
- [16] Poornima Narayanan Nambiar, Santha Kumar S, Ramshekhar Menon, Sruthi S Nair, GK Madhavalatha & Soumya Sundaram Horizontal gaze palsy and progressive scoliosis—a tale of two siblings with ROBO3 mutation. *Ophthalmic Genetics*. 2020, 41 (1); doi.org/10.1080/13816810.2020.1727537.
- [17] Merlini, Laura, Poncet, Antoine DTI measurements of non-decussating fibers in defective axon guidance disorders (Horizontal gaze palsy and progressive scoliosis and Joubert syndrome). *Journal of Pediatric Neuroradiology* 2013; doi: 10.3233/PNR-13054.
- [18] Julio Doménech, José María Tormos, Carlos Barrios, and Alvaro Pascual-Leone. Motor cortical hyperexcitability in idiopathic scoliosis: could focal dystonia be a subclinical etiological factor? *Eur Spine J*. 2010; 19 (2): 223–230; doi: 10.1007/s00586-009-1243-y.
- [19] Nutan Sharma. Neuropathology of Dystonia. *Tremor Other Hyperkinet Mov*. 2019; 9: 569; doi: 10.7916/d8-j6sx-b156.
- [20] Amit K., a, Nangunoori, Raj, Whiting, Donald M, Sangimino, Mark J. Scoliosis Secondary to Dystonia A Case Report and Review of the Literature Bhandutia,. *JBJS Case Connect*. 2017; 7 (3): e47; doi: 10.2106/JBJS.CC.16.00193.
- [21] Chi-Wei Lin, Chung-Ping Lo, and Min-Chien. Horizontal gaze palsy with progressive scoliosis: a case report with magnetic resonance tractography and electrophysiological study. *BMC Neurol*. 2018; 18: 75; doi.org/10.1186/s12883-018-1081-9.
- [22] Sicotte NL, Salamon G, Shattuck DW, et al. Diffusion tensor MRI shows abnormal brainstem crossing fibers associated with ROBO3 mutation. *Neurology*. 2006; 8; 67 (3): 51921; doi: 10.1212/01.wnl.0000227960.38262.0c.
- [23] Moore CEG, Schady W. Investigation of the functional correlates of reorganization within the human somatosensory cortex. *Brain*. 2000; 123: 1883–1895.
- [24] G. Defazio, MD; G. Abbruzzese. Primary cervical dystonia and scoliosis a multicenter case-control study. *Neurology*. 2003 25; 60 (6): 1012-5; doi: 10.1212/01.wnl.0000049932.22065.60.Jen J CC, Bosley TM, et al. Familial horizontal gaze palsy with progressive scoliosis maps to chromosome 11 q 23–25. *Neurology*. 2002 Aug 13; 59 (3): 432-5; doi: 10.1212/wnl.59.3.432.