

Thrombosis of the Cavernous Sinus Complicated by Aneurism of the Cavernous Segment of the Internal Carotid Artery: Case Report

Ewodo Touna Hilaire Dominique, Chislain De Chacus, Brandon Ekanmian, Mylene Tonga, Fanta Aida Ndieguene, Amadou Gallo Diop

Clinic of Neuroscience Ibrahima Pierre Ndiaye, Fann Hospital University, Cheikh Anta Diop University of Dakar (UCAD), Dakar, Senegal

Email address:

hilairtouna@gmail.com (E. T. H. Dominique)

To cite this article:

Ewodo Touna Hilaire Dominique, Chislain De Chacus, Brandon Ekanmian, Mylene Tonga, Fanta aida Ndieguene, Amadou Gallo Diop.

Thrombosis of the Cavernous Sinus Complicated by Aneurism of the Cavernous Segment of the Internal Carotid Artery: Case Report.

Clinical Neurology and Neuroscience. Vol. 6, No. 3, 2022, pp. 37-40. doi: 10.11648/j.cnn.20220603.11

Received: June 21, 2022; **Accepted:** July 11, 2022; **Published:** July 28, 2022

Abstract: *Introduction* Cavernous sinus thrombosis is a rare pathology. It usually follows locoregional infections or can also occur after facial surgery. Aneurysms of the cavernous segment of the internal carotid artery can be one of the complications of this condition which is a severe pathology that can be life-threatening. *Case presentation* Here is the case of a 32-year-old woman who has been maintained on oral contraceptive pills. She sought medical advice for an unusual headache that has been started three months after labor. Headaches were associated with paralysis of the left cranial nerve III related to partial cerebral venous thrombosis of the cavernous sinus on the ipsilateral side. The evolution of the condition while receiving oral anticoagulation drugs, was marked two weeks later by sudden onset, of motor deficit of the right side of the body associated with secondary generalized focal motor seizures. The etiology of this new symptomatology is the rupture of an aneurysm of the left Internal Carotid, causing a subarachnoid hemorrhage. *Conclusion* The cavernous sinus thrombosis complicates by an aneurysm of the Internal carotid artery is a rare association of pathology with severe prognostic. This report discusses the diagnostic approach, management, and prognosis of Cavernous Sinus Thrombosis.

Keywords: Cavernous Sinus Thrombosis, Aneurysm of the Internal Carotid, Complications

1. Introduction

Cavernous sinus venous thrombosis is a rare pathology. It usually follows locoregional infections, including dental infection [1], sinusitis [2], orbital cellulitis, pharyngitis, or otitis. It can also occur after facial surgery [3].

It is a severe pathology that can engage the vital and functional prognosis by complications such as sepsis, meningitis, subdural empyema, cerebral abscess, blindness, an extension of thrombosis, hypopituitarism, mycotic aneurysm of the Internal Carotid artery which can subsequently rupture and cause cerebral hemorrhage [3]. However, this last complication is rare.

In Senegal, internal carotid aneurysms on all its segments represent 28% of intracerebral aneurysms [4]. Those affecting the intra-cavernous segment remain relatively rare.

This case report, presents a patient who has been

exhibiting the association between these two conditions, which is considered as a real challenge in the management and prognosis of this condition.

2. Observation

A 32-year-old patient, mother of 4 children, three months postpartum, and on oral contraception with no known chronic pathology.

She was seen in consultation for a sudden onset of an unusual left hemicranial headache that had been progressing rapidly in the last 24 hours and was not relieved by the usual analgesics.

The headaches were of severe intensity, insomniac type of heaviness, and associated with projectile vomiting, without fever or constipation. Clinical examination showed ptosis, horizontal diplopia, and mydriasis of the left eye related to

the left cranial nerve III damage. Examination of the other cranial nerves and the rest of the neurological examination were unremarkable.

The diagnostic hypotheses of cerebral venous thrombosis, Migraine with aura, and expansive intracranial process were mentioned.

The cerebral venous thrombosis was retained in view of the patient's age, oral contraception, intracranial hypertension syndrome, involvement of cranial nerve III, and the mode of installation of the table in a rapidly progressive manner.

Cerebral angio-MRI revealed widening of the left cavernous compartment with contrast enhancement evoking partial thrombosis and partial filling of the right maxillary sinus (figure 1).

The biological assessment showed a CRP of 9.93mg/l, a white blood cell count of $8.51 \times 10^3/\text{ul}$, a platelet count of $345 \times 10^3/\text{g/dl}$, a hemoglobin level of 13.2g/dl, and INR of 1.26.

Cytobacteriological and biochemical examination of the cerebrospinal fluid was normal (leucocyte $< 1 \text{ element}/\text{mm}^3$, proteinorachia 0.6 g/l, glucorachia 0.6 g/l). Outpatient management consisted of oral anticoagulant treatment based on acenocoumarol (4 mg, $\frac{3}{4}$ tab per day) and analgesic treatment based on paracetamol (1g x 3 per day).

On the 14th day of treatment, the patient presented with a new episode of helmet-like headache with sudden onset during sleep accompanied by a focal tonic seizure of the right hemibody secondarily generalized, with biting of the tongue, post-ictal alertness disorder, and projectile vomiting.

Clinical examination showed proportional right pyramidal syndrome associated with meningeal syndrome and decreased alertness (Glasgow score of 13/15), with no notion of fever. The biological control assessment exhibited hyperleukocytosis at $13.1 \times 10^3/\text{dl}$ with neutrophil predominance, a hemoglobin level of 14g/dl and a platelet count of $491 \times 10^3/\text{ul}$. The control INR was 2.02.

The hypotheses of a subarachnoid hemorrhage (SAH) or an extension of cerebral venous thrombosis have been mentioned. The brain scan revealed spontaneous intraventricular hyperdensity suggestive of a subarachnoid hemorrhage (SAH) involving the left lateral ventricle, third and fourth ventricles associated with tetraventricular hydrocephalus (figure 2).

The severity score was III on the SAH WFNS (World Federation of Neurologic Surgeons) scale and 4 on the Fisher CT scale. An additional CT angiography was performed and revealed a sacciform aneurysm of the carotid ending that was developed at the expense of its posterior surface, which was partially thrombosed (figure 3).

The anticoagulant treatment was discontinued and the patient was admitted to the intensive care unit. She received anticonvulsant treatments (Mexazolam 1 tab/day), antihypertensive (Nimodipine 1 tab x 6/day), analgesic (Paracetamol injection 1g x 3/day), antibiotic (ceftriaxone 1g x2/day), and laxative (Macrogl 4000 1 sachet x2 /jr).

The prognosis was affected by the occurrence of cardiorespiratory arrest two days later while the patient was undergoing surgery.

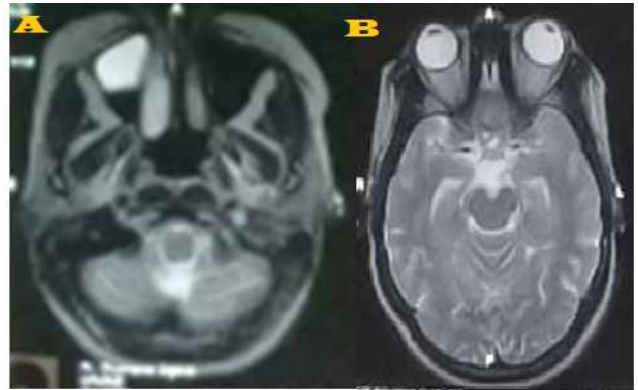

Figure 1. Axial section of cerebral MRI in T2 sequence showing partial filling of the right maxillary sinus (A). Thickening and widening of the left cavernous compartment enhanced by paramagnetic contrast (B).

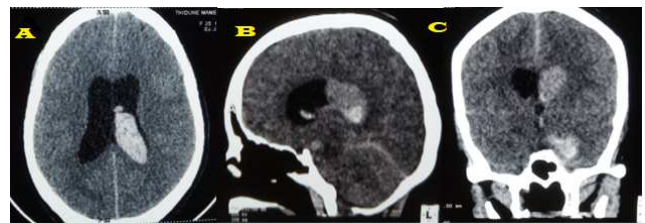

Figure 2. Spontaneous hyperdensity of the ventricles: left lateral ventricle, 3rd ventricle and 4th ventricle in relation to triventricular hemorrhage. A: Axial section, B: sagittal section C: coronal section.

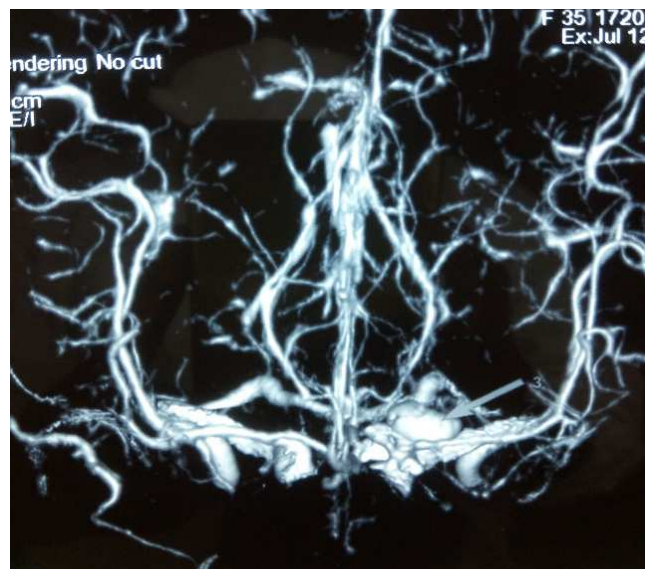


Figure 3. Cerebral angiography showing an aneurysm Sacciform of the left carotid ending partially thrombosed.

3. Discussion

Cerebral venous thrombosis is a relatively rare pathology in Senegalese series. The most common locations are: the superior longitudinal sinus and the lateral sinus [5, 6]. However, this patient presents with cavernous sinus

thrombosis which is less frequent in Senegal, and in the literature.

The etiologies of cavernous sinus thrombosis are multiple. Locoregional causes are more frequent and dominated by infections. General causes include pregnancy, trauma, surgery, taking estrogen and progestin [3]. The patient was three-month postpartum and maintained on oral contraceptive pills with right maxillary sinusitis, which suggests several possible etiologies.

In a case that was published in France in 2003, Philippeau explained the etiology to be sphenoidal and ethmoidal sinusitis complicated by osteomyelitis [7]. Mansare in 2020 reported a case of cavernous sinus thrombosis secondary to multifocal tuberculosis [8]. For this reason, locoregional infectious causes seem to be the most common etiology of cavernous sinus thrombosis.

The evolution of this pathology is variable. The most frequent complications in most cases are: Carotid-venous fistula [9, 10]; extension of cerebral venous thrombosis, subdural empyema, cerebral hemorrhage and rarely internal carotid aneurysm [11].

The patient presented on the 14th day of treatment for cavernous sinus thrombosis with a ruptured left internal carotid aneurysm. According to Wilson et al, the possible causes of these complications are the hematogenous spread of infectious microemboli to the vasa vasorum, occlusion by an infected embolism of the distal lumen of the artery, or to the contiguous spread of extravascular infections, such as sinusitis, orbital infection, or ear infection [12].

In the presented case, we found a locoregional infection which was maxillary sinusitis. However, it was contralateral to the thrombosis of the left cavernous sinus.

Ungsoo and al in 2010 in Korea described a similar case of a 62-year-old patient who presented with a right internal carotid aneurysm approximately four weeks after cavernous sinus thrombosis [13]. The patient received effective anticoagulation, analgesics and probabilistic antibiotic therapy, antihypertensives, and resuscitation measures, but surgery was not performed, and unfortunately, the deterioration was towards death. This reveals the management difficulty and poor prognosis of cavernous sinus thrombosis complicated by an internal carotid aneurysm.

4. Conclusion

Cavernous sinus thrombosis is a rare pathology, and its progression to an internal carotid aneurysm is exceptional. We reported the case of a 32-year-old patient with multiple risk factors who have been exhibiting these two pathologies with a fatal deterioration in her condition, which highlights the therapeutic challenges.

Conflict of Interest

The authors declare that they have no competing interests.

References

- [1] M'hamed RB, Chebbi G, Zgolli C, Mezri S, Brahem H, Balti M, et al. Thrombose du sinus caveux secondaire à une infection dentaire: une complication rare et potentiellement létale [Thrombosis of cavernous sinus secondary to dental infection: a rare and potentially lethal complication]. *J Tunis ORL Chir Cervico-Faciale*. 2013; 29: 70-3.
- [2] Dolapsakis C, Kranidioti E, Katsila S, Samarkos M. Cavernous sinus thrombosis due to ipsilateral sphenoid sinusitis. *BMJ Case Rep*. 29 janv 2019; 12 (1).
- [3] Plewa MC, Tadi P, Gupta M. Cavernous Sinus Thrombosis. In: StatPearls [Internet]. Treasure Island (FL): StatPearls Publishing; 2020 [cité 23 feb 2021] available: <http://www.ncbi.nlm.nih.gov/books/NBK448177/>
- [4] Thioub M, Mbaye M, Thiam AB, Zirhumana C, Sy C, Ndoeye N, et al. Microsurgical Treatment of Ruptured Intracranial Aneurysms in Sub-Saharan Africa: A Series of 102 Consecutive Cases Treated in Senegal. *World Neurosurg*. 1 févr 2018; 110: 226-31.
- [5] Diouf Mbourou N, Gaye MN, Nsouda A, Sounga Banzouzi PEG, Ndiaye M. Thrombose veineuse cérébrale au CHU de Fann, Dakar : à propos de 30 cas [cerebral venous thrombosis at FANN teaching hospital, DAKAR: About 30 cases]. *Afr J Neurol Sci* [Internet]. 2019 [cité 13 oct 2020]; Disponible sur: <https://pesquisa.bvsalud.org/gim/resource/pt/afr-201245>
- [6] Admin A, Niang FG, Diop AD, Niang I, Diouf KN, Thiam M, et al. Thrombose veineuse cérébrale : aspects tomodensitométriques au CHU FANN de Dakar-Sénégal [Cerebral venous thrombosis: CT scan aspects at the Fann teaching hospital, Dakar, Senegal]. *J Afr Imag Médicale J Afr Imag Méd* [Internet]. 12 nov 2020 [cité 18 févr 2022]; 12 (2). Disponible sur: <http://www.jaim-online.net/index.php/jaim/article/view/97>
- [7] Philippeau F, Hernet D, Thobois S, Turjman F, Bret P, Broussolle E, et al. Anévrisme de la carotide interne intracaverneuse compliquant une sinusite sphénoïdale [Aneurysm of the intra-cavernous internal carotid complicating a sphenoid sinusitis]. *Rev Neurol (Paris)*. 1 juill 2004; 160 (6): 713-5.
- [8] Mansare ML, Kouda DCA, Diallo IM, Ntenga P, Boubacar S, Gams MD, et al. Thrombose du sinus caveux: un cas clinique révélant une tuberculose multifocale et revue de la littérature [Cavernous sinus thrombosis: a clinical case revealing multifocal tuberculosis and literature review]. *Afr J Neurol Sci*. 2017; 36 (2): 33-42.
- [9] Al-Mufti F, Amuluru K, El-Ghanem M, Changa AR, Singh IP, Gandhi CD, et al. Spontaneous Bilateral Carotid-Cavernous Fistulas Secondary to Cavernous Sinus Thrombosis. *Neurosurgery*. 1 avr 2017; 80 (4): 646-54.
- [10] Hammami N, Fendri H, Krichene M, Arous A, Mahmoud M, Drissi S, et al. Les fistules carotido-caverneuses: du diagnostic au traitement endovasculaire [Carotido-cavernous fistulas: from diagnosis to endovascular treatment]. *J Neuroradiol*. 1 mars 2019; 46 (2): 100-1.
- [11] Geng B, Wu X, Malhotra A. Septic cavernous sinus thrombosis-Case series and review of the literature. *Clin Neurol Neurosurg*. oct 2020; 197: 106092.

- [12] Wilson WR, Hawrych A, Olan W. Rapid development of bilateral internal carotid artery aneurysm from sphenoid sinus aspergillosis. Skull Base Surg. 1998; 8 (4): 211-4.
- [13] Kim US, Kim JS, Kwon O-K, Hwang J-M. Complete Visual Recovery after Mycotic Aneurysm Embolization Complicated by Cavernous Sinus Thrombophlebitis. Korean J Ophthalmol KJO. oct 2010; 24 (5): 322-4.